



PATIENT PRESENTING CLINICAL SIGNS

Bubby Wishlow History: Chronic weight loss, progressive reduced appetite and lethargy, polydipsia.

SPECIES Physical Examination: N/A.

Feline Urinalysis: Normal.

CBC: Normal.

BREED Serum Biochemistry: Severely elevated lipase.

DSH Radiographic Findings: N/A.

SEX

MN

AGE

21 years

WEIGHT

6.1 kg

INTERPRETED BY

Remo Lobetti, BVSc,
MMedVet (Med), PhD,
Dipl. ECVIM

ULTRASONOGRAPHIC EXAMINATION OF THE ABDOMEN

Urinary System

Full urinary bladder with a normal thickness and appearance of the wall. Normal anechoic urine with no sediment or uroliths evident.

Normal trigone area, proximal urethra, and iliac blood vessels.

Normal iliac lymph nodes. Ureters not visualized.

Normal renal size (left 3.6 cm, right 4.2 cm) with increased echogenic appearance, some loss of cortico-medullary differentiation, and normal blood flow, capsule, and pelvis.

Reproductive System

N/A.

IMAGING PERFORMED BY

Dr Alastair Westcott,
DVM

Adrenal Glands

Normal shape, echogenic appearance, size, and position. Left 0.58 x 0.44, right 0.98 x 0.27/0.31 cm.

HOSPITAL NAME

Spleen

Normal size (1 cm) with a diffuse hyperechogenic and fine nodular appearance. Smooth homogenous parenchyma, smooth curvi-linear capsule, and normal vasculature. No evidence of inflammatory, neoplastic, infarction, or infiltrative changes noted.

REFERRING VET

Dr Alastair Westcott,
DVM

Liver

Normal size, echogenic appearance, and portal markings. No nodules or masses evident. Full gall bladder containing normal anechoic bile. Normal thickness and echogenic appearance of the gall bladder wall. Normal bile duct.

INVOICE

302741

DATE

2 /10/22



PATIENT *Gastrointestinal*

Bubby Wishlow

Normal appearance of the stomach, duodenum, ileo-cecal junction, and colon with no loss of layering, normal wall thickness (duodenum 0.4 cm) and peristaltic activity, and no distension of the lumen. Prominent hypoechoogenic appearance of the submucosal layer of the small intestine but with no loss of layering or distention of the lumen.

SPECIES

Feline

Pancreas

BREED

DSH

Normal size (right 1 cm, left 0.8 cm) with a diffuse hypoechoogenic, cystic, and nodular appearance. Irregular capsule. Hyperechoogenic appearance of the mesentery and fat surrounding the pancreas. Cyst-like structure with associated hyperechoogenic irregular and poorly perfused nodule (0.9 x 1.5 cm).

SEX

MN

Free Abdomen

AGE

21 years

No mesenteric lymphadenomegaly.
No ascites.

ULTRASONOGRAPHIC FINDINGS

WEIGHT

6.1 kg

Primary Findings:

- Nodular/cystic pancreatitis.
- Enteropathy.
- Splenic pathology?

INTERPRETED BY

Remo Lobetti, BVSc,
MMedVet (Med), PhD,
Dipl. ECVIM

Secondary Findings:

- Age-related renal changes.

IMAGING PERFORMED BY

Dr Alastair Westcott,
DVM

INTERPRETATION OF THE FINDINGS & FURTHER RECOMMENDATIONS

Although the appearance of the pancreas is indicative of chronic-active pancreatitis, with the cystic/nodular structures neoplasia would be an important differential diagnosis.

HOSPITAL NAME

Etiologies for the enteropathy would be an incidental age-related change, inflammatory bowel disease, dietary hypersensitivity, and parasitic enteritis.

REFERRING VET

Dr Alastair Westcott,
DVM

Although the splenic changes may merely be an incidental age-related change, splenitis, granulomatous disease, and infiltrative neoplasia would be possible differential diagnoses.

INVOICE

302741

Further assessment needs to be based on the results of the FNA cytology of the pancreas but could include fecal analysis, fPL/PSL assay, FNA cytology of the spleen, and 3-view thoracic radiographs.

DATE

2 /10/22

Specific therapy would be dependent on an etiological diagnosis.



PATIENT IMAGES

Bubby Wishlow

Pancreas

SPECIES

Feline

BREED

DSH

SEX

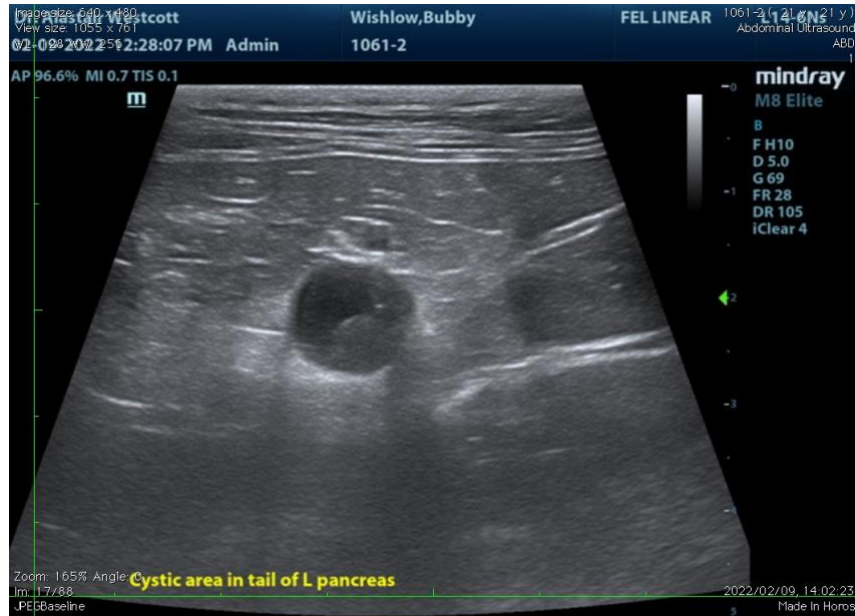MN

AGE

21 years

WEIGHT

6.1 kg



INTERPRETED BY

Remo Lobetti, BVSc,
MMedVet (Med), PhD,
Dipl. ECVIM

IMAGING PERFORMED BY

Dr Alastair Westcott,
DVM

HOSPITAL NAME

REFERRING VET

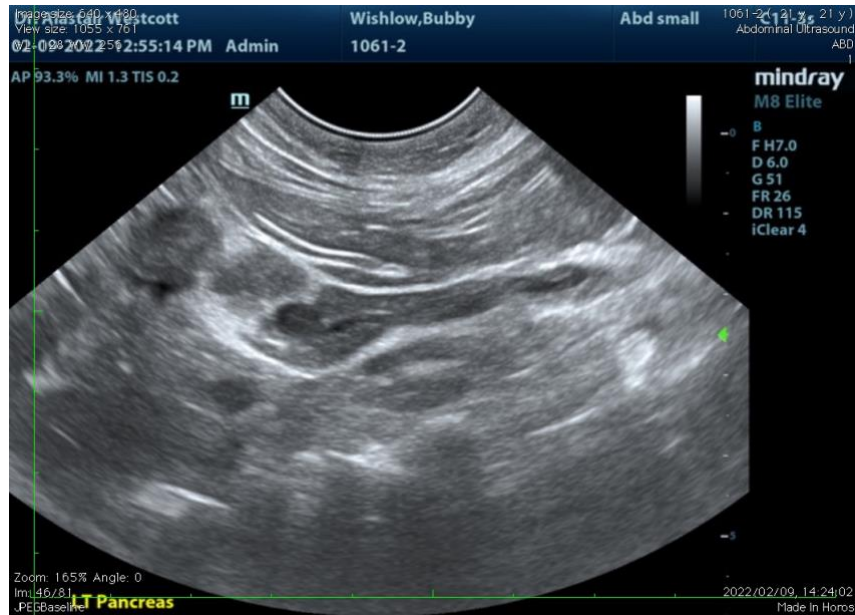Dr Alastair Westcott,
DVM

INVOICE

302741

DATE

2 /10/22





PATIENT

Bubby Wishlow

SPECIES

Feline

BREED

DSH

SEX

MN

AGE

21 years

WEIGHT

6.1 kg

Spleen

INTERPRETED BY

Remo Lobetti, BVSc,
MMedVet (Med), PhD,
Dipl. ECVIM

IMAGING PERFORMED BY

Dr Alastair Westcott,
DVM

HOSPITAL NAME

REFERRING VET

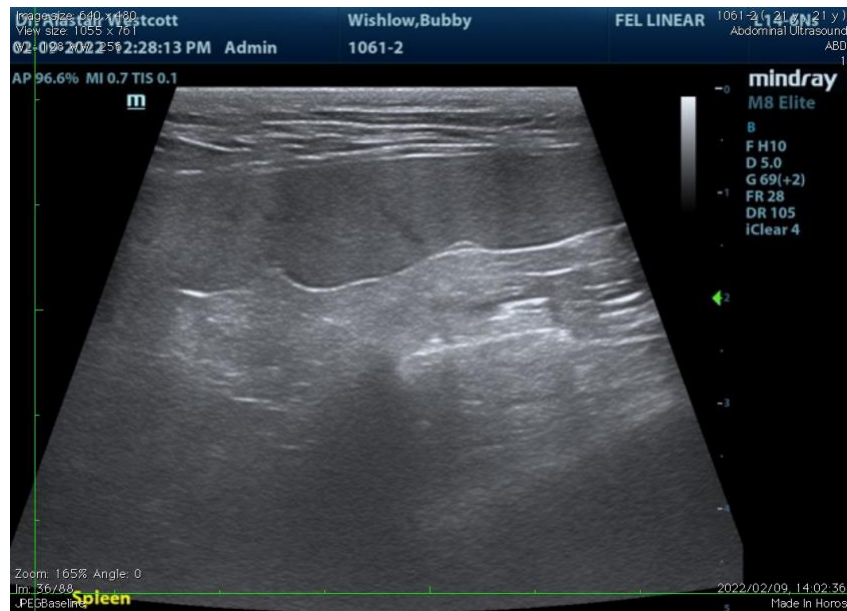
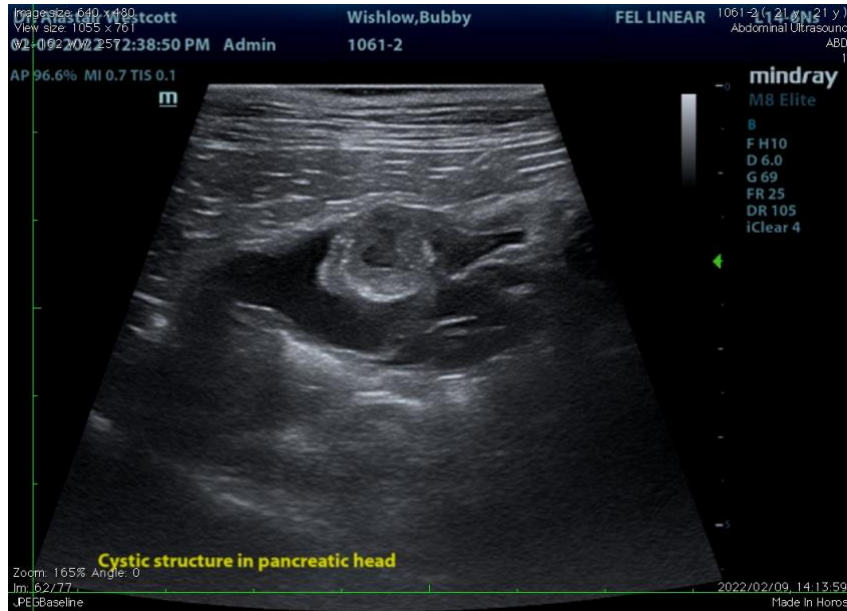Dr Alastair Westcott,
DVM

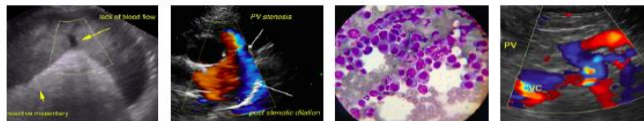
INVOICE

302741

DATE

2 /10/22





PATIENT Small intestine

Bubby Wishlow

SPECIES

Feline

BREED

DSH

SEX

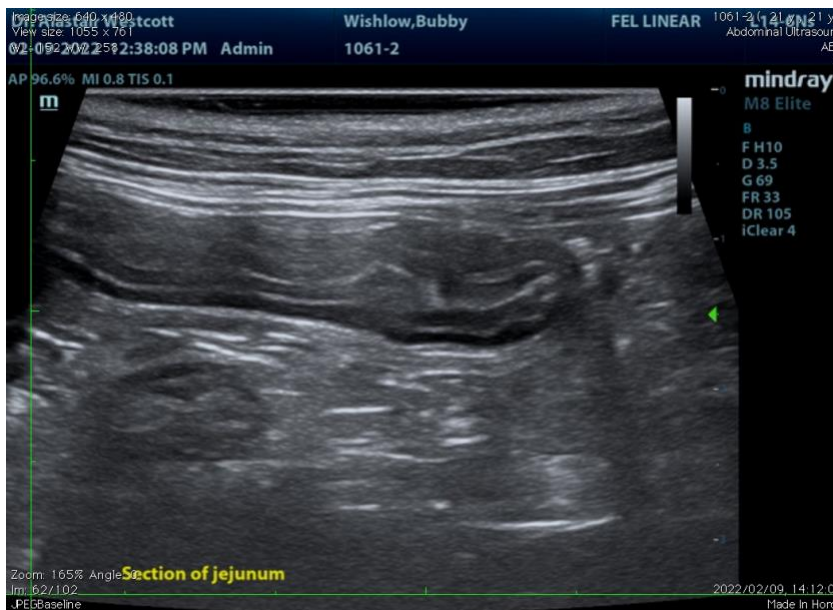MN

AGE

21 years

WEIGHT

6.1 kg



INTERPRETED BY

Remo Lobetti, BVSc,
MMedVet (Med), PhD,
Dipl. ECVIM

The information and recommendations provided are based on the images presented by the referring veterinarian. No evaluation can be communicated regarding pathology that was not visible in the image/video clips provided.

Thank you for this referral. If the clinical or image interpretation does not parallel your findings or if I can be of any further assistance, please contact me.

IMAGING PERFORMED BY

Dr Alastair Westcott,
DVM

Remo Lobetti, BVSc, MMedVet (Med), PhD, Dipl. ECVIM (Internal Medicine)
rlobetti@mweb.co.za

HOSPITAL NAME

REFERRING VET

Dr Alastair Westcott,
DVM

INVOICE

302741

DATE

2 /10/22